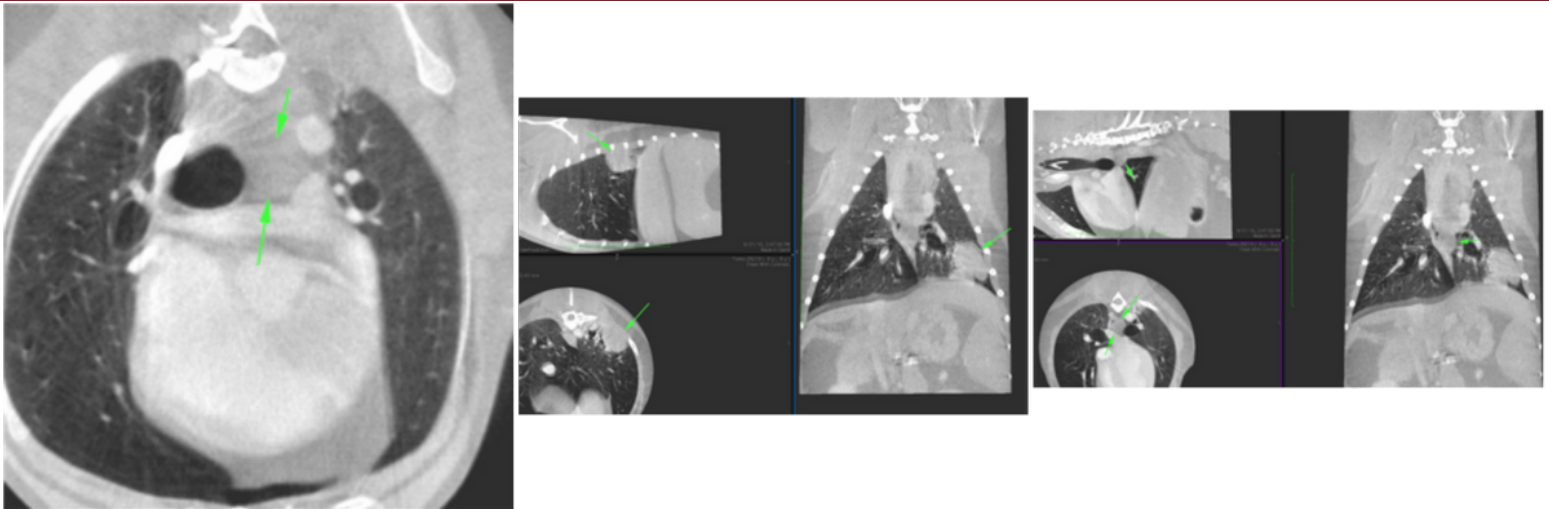


ONLY WITH
VIMAGO

SMALL ANIMAL CASE STUDY REVIEW

By Dr. Robert O'Brien, DVM, DACVR

HIGH-DEFINITION COMPUTED TOMOGRAPHY CASE REVIEW
- LUNG MASS



PATIENT AND HISTORY

8-year-old, female, unaltered Schnauzer who referred for consultation & abdominal ultrasound due to possible lung mass.

The owner reports however that dog is not showing any signs of illness.

History of a liver shunt. Recent chest radiographs revealed lung mass involving the left side of the chest cavity. The recent lab test results showed no significant findings. The cytology results from the lung mass interpreted by our in-house clinical pathologist revealed cancer involving a lymph node. There was no lung tissue, only lymph node identified. Histiocytic lymphosarcoma is the suspected type of cancer.

CONCLUSION:

1. Lungs mass: presumed carcinoma (pulmonary, bronchoalveolar)(unlikely granuloma, abscess)
2. Lung alveolar disease: atelectasis (or pneumonia, atypical neoplastic infiltration)
3. Tracheobronchial LN: possible metastatic adenopathy (less likely reactive)

FINDINGS

Lung:

- a. Mass: 3.0 x 2.5 x 2.5 cm, in caudodorsal left region. Uniformly soft tissue and uniformly well enhanced.
- b. alveolar lesion contiguous
- c. no nodules seen

Mediastinum:

- a. Middle tracheobronchial LN: enlarged, poorly contrast enhancing, 1.8 x 1.6 x 1.6 cm
- b. Left tracheobronchial LN: enlarged, poorly contrast enhancing, 1.0 cm wide

Pleural space: Normal

Body wall: Normal

RECOMMENDATIONS:

Palliation: mass excision and "cherry pick" adenectomy